

Three-dimensional morphometric analysis of segmental glomerulosclerosis in the rat

ANDREA REMUZZI, ROSSANA PERGOLIZZI, MICHAEL S. MAUER, and TULLIO BERTANI

Istituto di Ricerche Farmacologiche "Mario Negri", 24100 Bergamo, Italy and Department of Pediatrics, University of Minnesota School of Medicine, Minneapolis, Minnesota 55455, USA

Three-dimensional morphometric analysis of segmental glomerulosclerosis in the rat. In idiopathic nephrotic syndrome, and in experimental models of nephrosis, changes of visceral epithelial cells involve the entire glomerular population while segmental sclerotic changes are reported to affect only a certain number of glomeruli. Because conventional determination of the percentage of glomeruli affected by sclerotic lesions is usually based on the examination of randomly selected sections, we wondered whether glomeruli appearing normal in a given section could be affected by sclerosis in other regions of the capillary tuft (CT). To assess the real incidence and the spatial extension of sclerotic changes at the level of single glomerulus, we used serial-section morphological analysis to measure the volume of the glomerulus and that of sclerosis lesions. In glomeruli from control rats and in glomeruli from adriamycin (ADR) treated rats surface area of Bowman's capsule (BC), CT and sclerotic regions were measured using stereology techniques in all the consecutive sections containing each individual glomerulus, and corresponding volumes were then calculated. Mean volume of BC and CT were not significantly different between control and ADR rats (0.71 ± 0.03 and 0.53 ± 0.03 vs. 0.76 ± 0.04 and $0.53 \pm 0.02 \mu\text{m}^3 \times 10^{-6}$, respectively). The distribution of glomerular volume parameters in the ADR rats were more spread out than in control animals, indicating that some glomeruli became smaller while other became larger. No sclerotic changes were found in control rats, while in the three ADR rats 94, 90 and 92% of glomeruli, respectively, were affected by sclerotic lesions. Conventional counting of glomeruli affected by sclerosis in single sections (on average 39, 27 and 23%) highly underestimated the percentage of sclerotic glomeruli. Despite sclerotic lesions involved almost entirely in the glomerular population, they were limited to a small fraction of the CT volume (on average 3.5, 2.2 and 2.6% in each animal). Our results indicate that: 1) adequate quantification of the percentage of glomeruli affected by sclerosis can be made only with three-dimensional morphologic analysis of the entire glomerulus, as glomeruli appearing normal in a given section can show sclerosis changes in regions far from the section of examination; and 2) in the model of ADR nephrosis the initiation of sclerotic processes simultaneously affects almost the entire glomerular population.

The term "focal and segmental glomerulosclerosis and hyalinosis" (FSGH) is used to designate a pathological pattern in which some glomeruli show localized areas of sclerosis and hyalinosis in the capillary tuft (CT). Glomerular sclerosis is characterized by excessive production of mesangial cell matrix

and collapse of capillaries. Foci of a strongly eosinophilic and PAS positive material may be included or separated by sclerotic areas and constitute hyalinosis lesions. Adhesions of the capillary tuft to Bowman's capsule are common. Lipid containing endothelial cells may be seen. In the setting of nephrotic syndrome FSGH was first described by Rich in 1957 [1] in children affected by lipid nephrosis. He found that focal sclerotic lesions preferentially involved juxtamedullary glomeruli. In the adult population FSGH is found in 15 to 20% of patients with idiopathic nephrotic syndrome, and generally it has a progressive course to renal failure [2].

In recent years two models of nephrotic syndrome, which closely mimic the pathological changes and clinical course of FSG occurring in man, have been developed in experimental animals. Chronic administration of aminonucleoside of puromycin (PA) is the first described model of nephrotic syndrome with FSG [3]. More recently, ADR-induced glomerulosclerosis has emerged as a new model of chronic proteinuria evolving to FSG [4, 5].

In these two models, as well as in other conditions evolving to FSG, sclerotic lesions are usually confined to only few glomeruli. This would suggest that, at least in the initial phase of the process, the noxious insult is unevenly distributed among the nephron population. However, ultrastructural examination of glomeruli in nephrotic patients with FSG, as well as in ADR and PA rats, shows that characteristic changes of glomerular visceral epithelial cells, consisting of a spread fusion of foot processes and marked swelling of their cytoplasm, are rather diffuse and uniformly distributed to all glomeruli [6–8]. Therefore it is surprising that the process of glomerular sclerosis affects only a fraction of the glomerular population.

One possible answer to this question is that conventional determinations of the percentage of sclerotic glomeruli based on the examination of a single section, or at the most of a few random sections, might introduce bias in that glomeruli appearing normal could be affected by sclerosis and hyalinosis in some areas of the glomerular tuft not in the plane of the section. This situation could then lead to misinterpretation of the real extent of sclerosis in the glomerular population. In order to assess the real incidence and the spatial extension of sclerosis and hyalinosis changes in the entire glomerular structure, we have used serial-section morphologic analysis to obtain complete reconstruction of the glomerulus and to calculate the amount of CT volume affected by sclerosis and hyalinosis. We have applied

Received for publication May 2, 1989
and in revised form April 17, 1990
Accepted for publication May 5, 1990

© 1990 by the International Society of Nephrology

this method to measure glomerular volume and the volume of sclerosis and hyalinosis lesions in rats treated with ADR, in a relatively early phase of FSGH, and in normal rats taken as controls.

Methods

Eleven Sprague-Dawley CD-COBS male rats (Charles River Italia, Calco, Italy) weighing approximately 250 g at the beginning of the study were used. One group of rats ($N = 6$) was treated with 5 mg/kg of ADR (Atriblastina, Farmitalia Carlo Erba, Milan, Italy), as a single injection through the tail vein as previously described [9]. The other group, used as a control, received the vehicle alone. Ten weeks after ADR or vehicle injection, rats were anaesthetized with ether and sacrificed. Before the sacrifice proteinuria (determined with the Coomassie blue method [10]) was 439 ± 50 and 10 ± 3 mg/day in the ADR and in the control group, respectively. Fragments of kidney were fixed in Dubosq-Brazil fluid (80% alcohol, 150 ml; formol, 60 ml; acetic acid, 15 ml; picric acid, 1 g), embedded in paraffin and stained with periodic acid staining (PAS).

Pathological examination of kidneys of ADR treated animals revealed focal and segmental glomerulosclerosis and hyalinosis in all animals. Percentage of glomeruli affected by sclerotic changes (based on examination of at least 130 glomeruli) ranged from 28 to 44%, with a mean value of 35%. Three of the six nephrotic animals were selected for serial section examination for having a percentage of sclerotic glomeruli and urinary protein excretion rate near the average group values (35% and 426 mg/day, respectively). Pathological examination of control animals did not reveal any glomerular lesions. Analogously, three rats from the control group were randomly selected for serial section study. From the six selected animals, one hundred consecutive sections ($4 \mu\text{m}$ thick) were stained with PAS.

We examined, initially, a section located approximately in the middle of the tissue, hereafter referred as "starting section". Fifty glomeruli from each nephrotic rat and 30 from each control rat were chosen for serial section examination. The distribution of the BC area of these glomeruli was representative of the BC area distribution of all glomeruli present in the section.¹ For each selected glomerulus the profiles of the BC, of the CT and of the sclerosis and hyalinosis lesions were manually drawn using the projected image of the glomerulus in a drawing tube (Zeiss, Oberkochen, FRG), mounted on the microscope, with a final magnification of $\times 313.2$. This procedure was repeated in all the sections preceding and following the "starting section" until the glomerulus completely disappeared. Glomerular sclerosis was defined by an increase of mesangial matrix substance associated with capillary wall wrinkling and collapse. The sclerotic lesions might or might not be associated with adhesion to Bowman's capsule. Hyalinosis was defined by the presence of PAS-positive hyalin material included or separated by sclerotic regions in the subendothelium or in the mesangium.

¹ To verify that the glomeruli selected for serial section analysis were representative of the glomerular population we compared BC area distribution (measured with the method described below) of all glomeruli in two starting sections (one from an ADR rat animal and one from a control animal) with the corresponding BC area distribution of the glomeruli selected for serial section study. BC area in the starting section of a control rat (rat #1) averaged $7.7 \mu\text{m}^2 \times 10^{-3}$ (range 2.9 to 11.4, $N = 131$), BC area of selected glomeruli in the same section averaged $8.0 \mu\text{m}^2 \times 10^{-3}$ (range 3.5 to 11.2, $N = 30$). Analogously, for an ADR animal (rat #1) BC area of all glomeruli in the starting section averaged $7.9 \mu\text{m}^2 \times 10^{-3}$ (range 2.8 to 13.7, $N = 144$), while in selected glomeruli BC area averaged $8.1 \mu\text{m}^2 \times 10^{-3}$ (3.2 to 13.1, $N = 50$).

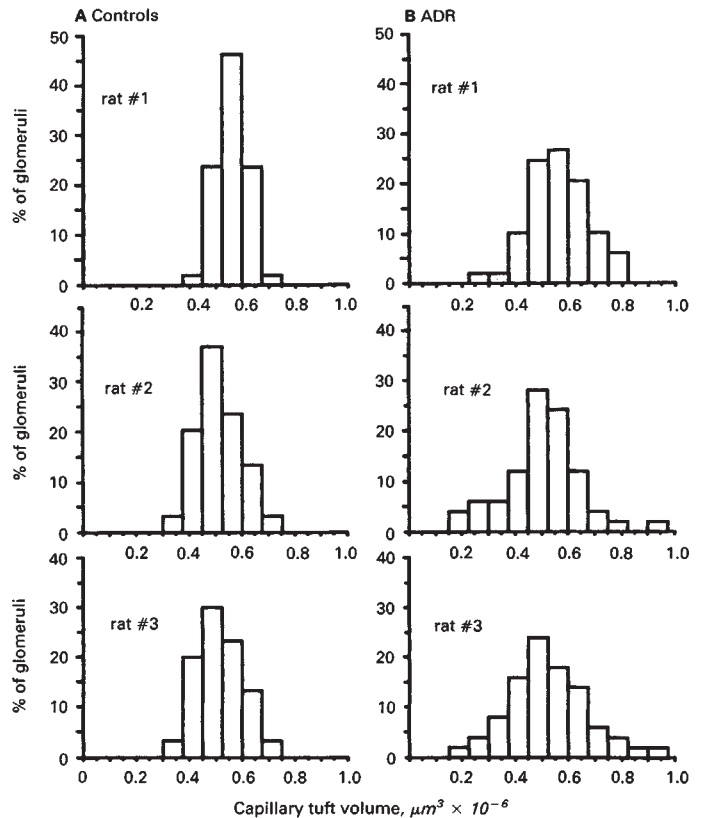


Fig. 1. Frequency distribution histograms of capillary tuft volume in control rats and in rats treated with ADR.

Surface area of the outlines of BC, CT and sclerotic regions were determined with stereological methods [11] using a grid of 30×50 points. An average of 79 points (range 3 to 161) were counted inside the CT profiles and 4 points (1 to 26) on average were counted in the outline of the sclerotic regions. Volume of BC, CT and sclerotic regions for each glomerulus were then calculated as the sum of the measured surface areas multiplied by the section thickness ($4 \mu\text{m}$). The percentage of CT volume affected by sclerosis in each glomerulus was calculated and, in each individual section, the number of selected glomeruli affected by sclerosis was counted.

Statistical analysis was performed using unpaired Student's t -test or linear regression analysis. Statistical significance was defined as $P < 0.05$. All data are expressed as means \pm standard deviation.

Results

Glomerular volumes

Glomerular volume measured in normal and in nephrotic rats are reported in Table 1. No significant difference in mean BC or CT volume were observed between the two animal groups. Analogously, no significant difference was observed comparing

Table 1. Glomerular volume determinations

Group	Number of glomeruli examined	Bowman's capsule	Capillary tuft	Sclerosis	Sclerosis %
		$\mu\text{m}^3 \times 10^{-6}$			
Control rat #1	30	0.71 ± 0.09	0.56 ± 0.06	—	—
Control rat #2	30	0.68 ± 0.16	0.50 ± 0.10	—	—
Control rat #3	30	0.73 ± 0.16	0.54 ± 0.12	—	—
Mean of 3 control rats		0.71 ± 0.03	0.53 ± 0.03	—	—
ADR rat #1	50	0.78 ± 0.15	0.55 ± 0.11	0.017 ± 0.015 (0-0.065)	3.5 ± 4.2 (0-21.0)
ADR rat #2	50	0.72 ± 0.21	0.51 ± 0.15	0.009 ± 0.008 (0-0.033)	2.2 ± 2.6 (0-16.1)
ADR rat #3	50	0.80 ± 0.24	0.52 ± 0.15	0.012 ± 0.011 (0-0.057)	2.6 ± 2.0 (0-10.0)
Mean of 3 ADR rats		0.76 ± 0.04	0.53 ± 0.02	0.013 ± 0.004	2.8 ± 0.7

Values are mean \pm SD. Range interval is in parenthesis.

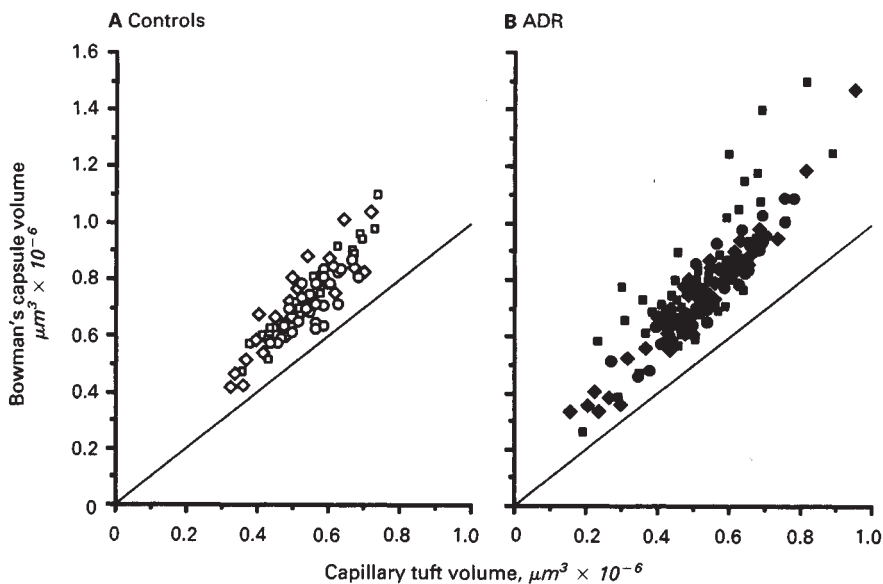


Fig. 2. Relationship between glomerular capillary tuft volume and Bowman's capsule volume in control rats and in ADR treated rats. Symbols are: (circles) rat #1; (diamonds) rat #2; (squares) rat #3.

the volumes of all glomeruli ($N = 90$) examined from normal animals with those ($N = 150$) examined from nephrotic rats. The frequency distribution histograms of the CT volume for each individual animal are reported in Figure 1. In control rats CT volume was normally distributed around the mean. In ADR treated rats CT volume distribution was still normal but more spread around the mean as compared to control rats, indicating that during the course of the disease some glomeruli had become larger and, at the same time, others had become smaller.

To illustrate the relation between CT volume and BC volume, their respective values, for each glomerulus, are represented in Figure 2. The line of identity in the graph represents the hypothetical condition in which CT and BC volume are equal. As expected, points representing normal glomeruli show that when glomerular CT volume increases BC volume also increases proportionally. Points representing nephrotic glomeruli are more spread around the mean, as compared to normal glomeruli. Moreover, it can be observed that reduction or

increase in glomerular volume were not confined to CT but were paralleled by changes in BC volume.

Sclerosis

As reported in Tables 1 and 2, no sclerotic changes were found in glomeruli from control rats, while in ADR rats 47, 45 and 46 glomeruli out of 50 were affected by sclerotic regions in each animal studied. Sclerotic regions were confined to a small fraction of the CT volume (on average 2.8%, see Table 1). As shown by the frequency distribution histogram reported in Figure 3 sclerosis volume was larger than 10% of the CT volume in only few glomeruli, the majority of sclerosed glomeruli being affected by sclerosis changes in less than 10% of the CT volume.

To provide a more precise view of the incidence and the extent of the sclerotic regions the 50 glomeruli analyzed from one ADR rat (rat #1) are schematically represented in Figure 4. Each glomerulus is represented as viewed in a direction parallel to the tissue sections, with the horizontal dimension of the

Table 2. Percentage of sclerotic glomeruli

	Rat #1	Rat #2	Rat #3	
Single sections	Starting section	32%	20%	14%
	Minimum	30%	8%	14%
	Maximum	58%	38%	34%
	Mean \pm SD	39 \pm 9%	27 \pm 8%	23 \pm 7%
Total number of sclerotic glomeruli	94% (47/50)	90% (45/50)	92% (46/50)	

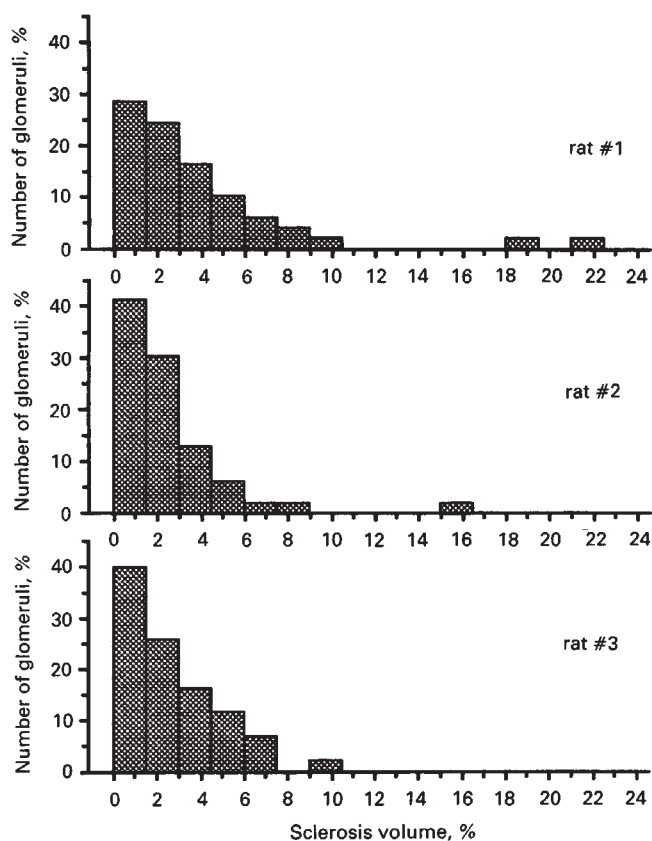


Fig. 3. Frequency distribution histograms of percentage of glomerular capillary tuft volume affected by sclerosis in the ADR treated rats.

drawing proportional to the mean diameter of the CT in the corresponding section. Sclerotic regions are represented by black areas, with horizontal dimension being proportional to their mean diameter in the corresponding section. The continuous line reported in the figure represents the starting section. As shown by the diagram, only 16 glomeruli (32%, Table 2) showed sclerotic regions in the starting section, while in the other 34 glomeruli this section did not cross areas affected by sclerotic changes. However, the majority of these glomeruli (31 out of 34) showed sclerotic regions in other sections, and in only three glomeruli the CT appeared completely free from sclerosis.

We have also observed that the percent of glomeruli affected by sclerosis varied considerably among the sections examined. In single sections the percent of glomeruli selected for serial section study and affected by sclerosis ranged from 30 to 58%, from 8 to 38%, and from 14 to 34%, respectively, for the three nephrotic rats, indicating that the conventional method of

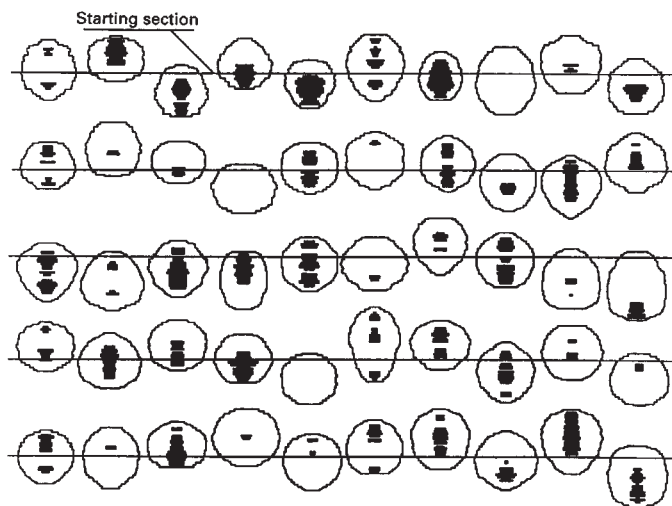


Fig. 4. Schematic representation of spatial distribution of sclerotic lesions within each individual glomerulus from a rat treated with ADR (rat #1).

quantification of segmental sclerosis lesions is intrinsically highly variable.

The measure of the real CT volume in this population of partially sclerotic glomeruli allowed us to determine the relationship between CT volume and sclerosis volume. No significant correlation was found between CT volume and sclerosis volume when regression analysis was applied to all 150 glomeruli examined from nephrotic animals ($r = 0.08$, NS). Applying regression analysis only to the glomeruli from a single animal, sclerosis volume was inversely correlated with CT volume for one rat (rat #1, $r = 0.49$, $P < 0.01$), but no such correlation was found for the other two animals studied ($r = 0.03$, NS and $r = 0.07$, NS, respectively). However, the correlation between CT and sclerosis volume observed for rat #1 was highly dependent upon two data points, the two most sclerotic glomeruli (no significant correlation was found when regression analysis was confined to glomeruli having sclerosis volume $< 0.05 \mu\text{m}^3 \times 10^{-6}$).

Discussion

This study documents that the development of FSGH in ADR nephrosis involves virtually the entire glomerular population. Measurements of volume parameters and examination of 50 glomeruli in three nephrotic animals revealed that 94, 90 and 92% of glomeruli, respectively, for the three animals were affected by sclerosis. Despite the high incidence of FSGH sclerotic changes occupied only a small fraction of the glomerular CT volume (on average 3.5, 2.2 and 2.6%, respectively, for the three animals).

As mentioned previously our experimental work was devoted to understand why, in this model of nephropathy, sclerotic changes are usually observed in only few glomeruli while ultrastructural damages are uniformly distributed throughout the glomerular population [4]. Our results showed that conventional determination of sclerotic glomeruli, based on single section examination, is highly variable and underestimates the percentage of sclerotic glomeruli (mean percentage of sclerotic glomeruli in single sections was 39, 27 and 23% for the three

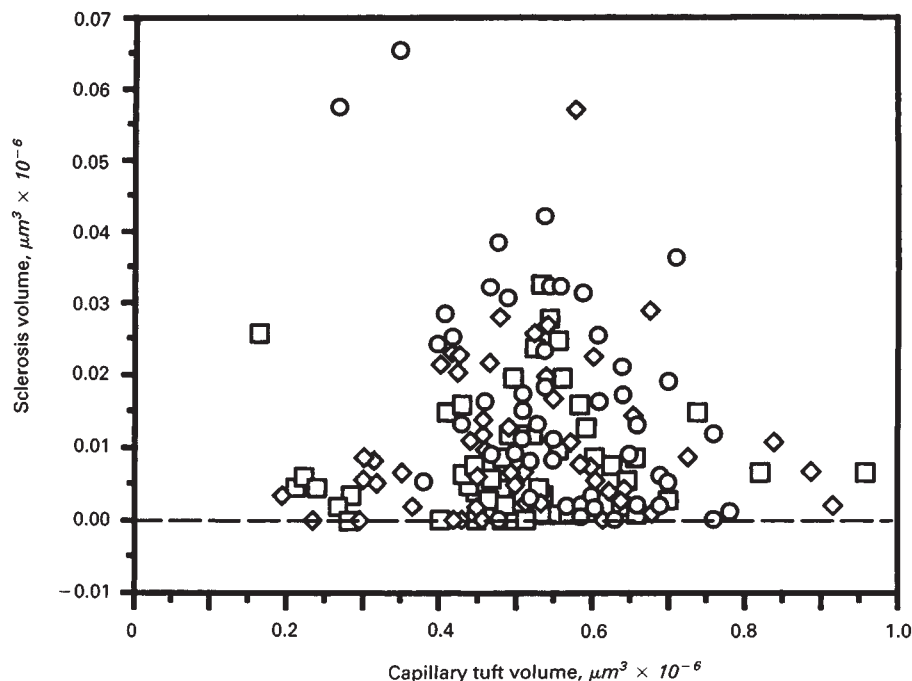


Fig. 5. Relationship between glomerular capillary tuft volume and sclerosis volume for all glomeruli examined from three ADR treated rats (linear regression analysis, $N = 150$, $r = 0.089$, NS). Symbols are: (○) rat #1; (◇) rat #2; (□) rat #3.

animals studied). Actually serial section analysis revealed that most of glomeruli appearing normal in a given section were affected by sclerosis in regions out of the section of examination (Fig. 5). Therefore our results indicate that ADR nephrosis is a model of "diffuse" glomerulosclerosis rather than of "focal" glomerulosclerosis as reported till now [5, 6]. It is possible that this concept applies to other experimental models of FSGH, and to some glomerular diseases in humans, which are also considered "focal" on the basis of single section examinations.

Finding of sclerotic areas in most glomeruli from nephrotic animals indicates that a portion of capillary network underwent obstruction, or dimensional alterations, with functional adaptation of the remaining branches. These changes may reproduce at the level of single glomerulus what has been previously shown at the whole kidney level [12, 13]. Actually surgical removal of functioning nephrons induces adaptive changes in the remaining ones possibly responsible for glomerular structural damage, and further drop out of nephron units [14].

It has been previously reported that glomerular hypertrophy and sclerosis are two correlated phenomena in a variety of experimental settings and in human glomerulopathy [15–17]. This correlation is based on the observation that glomerular hypertrophy precedes the development of sclerotic lesions and that subsequently the glomerulus become smaller as sclerosis advances [16]. Other studies have shown, however, that protection of kidney structure was not always associated with prevention of glomerular hypertrophy [18, 19]. We have found that mean CT and BC volumes, determined at the level of the single glomerulus, were comparable in the ADR and in the control rats. This result is in line with the observation of Fries et al [20], who reported that 11 weeks after a single injection of ADR glomerular volume was not significantly different in control and in ADR treated rats.

One could argue that the lack of diffuse hypertrophy in our

experimental conditions could be due to the high incidence of sclerotic glomeruli that could have undergone shrinkage [17]. Linear regression analysis of CT and sclerosis volume failed to show a significant correlation between glomerular volume and extension of sclerosis lesions. Considering glomeruli from individual animals, only one of the three animal studied showed a significant correlation between CT volume and sclerosis volume, with a low correlation coefficient ($r = 0.49$). These results do not support the concept that glomerular hypertrophy is the major factor responsible for the development of sclerosis lesions in ADR nephrosis. However, to achieve more definitive understanding of the relationship between glomerular hypertrophy and development of sclerosis in this experimental setting, the present methodological approach should be applied to serial studies to monitor glomerular volume parameters from the time of ADR administration to the time of development of sclerosis changes.

In conclusion our study demonstrates that: 1) conventional analysis of single sections for quantification of the percentage of glomeruli affected by sclerosis greatly underestimates the incidence of sclerosis, and more adequate estimation can be made with three-dimensional morphometrical analysis of the entire glomerulus; 2) in ADR nephropathy, the early sclerotic process affected almost all glomeruli and was confined, rather uniformly, to a small portion of the glomerular CT; and 3) in our experimental setting the volume of sclerosis lesions did not correlate with glomerular volume.

Acknowledgments

We thank Luca Bonetti for the help in computations and Dr. Giuseppe Remuzzi for helpful discussion. The authors also thank Farmitalia Carlo Erba, Milano, Italy for kindly providing Adriablastina through the courtesy of Prof. Claudio Praga.

Reprint requests to Dr. Andrea Remuzzi, Istituto di Ricerche Farmacologiche "Mario Negri", Via Gavazzeni, 11, 24100 Bergamo, Italy.

References

1. RICH AR: A hitherto underscribed vulnerability of the juxtamedullary glomeruli in lipid nephrosis. *Bull Johns Hopkins Hosp* 100:173-186, 1957
2. CAMERON JS, TURNER DR, OGG CS, CHANTLER C, WILLIAMS DG: The long-term prognosis of patients with focal segmental glomerulosclerosis. *Clin Nephrol* 10:213-218, 1978
3. GLASSER RJ, VELOSA JA, MICHAEL AF: Experimental model of focal sclerosis. I. Relationship to protein excretion in aminonucleoside nephrosis. *Lab Invest* 36:519-526, 1977
4. BERTANI T, ROCCHI G, MECCA G, SACCHI G, REMUZZI G: Adriamycin-induced chronic proteinuria: A new model of glomerular focal sclerosis. (abstract) *Kidney Int* 23:192A, 1983
5. OKUDA S, OH J, TSURUDA H, ONOYAMA K, FUJIMI S, FUJISHIMA M: Adriamycin-induced nephropathy as a model of chronic progressive glomerular disease. *Kidney Int* 29(2):502-510, 1986
6. BERTANI T, ROCCHI G, SACCHI G, MECCA G, REMUZZI G: Adriamycin-induced glomerulosclerosis in the rat. *Am J Kidney Dis* 7(1):12-19, 1986
7. WEENING JJ, RENNKE HG: Glomerular permeability and polyanion in adriamycin nephrosis in the rat. *Kidney Int* 24:152-159, 1983
8. RYAN GB, KARNOVSKY MJ: An ultrastructural study of the mechanism of proteinuria in aminonucleoside nephrosis. *Kidney Int* 8:219-232, 1975
9. BERTANI T, POGGI A, POZZONI R, DELAINI F, SACCHI G, THOUA Y, MECCA G, REMUZZI G, DONATI MB: Adriamycin-induced nephrotic syndrome in rats. Sequence of pathologic events. *Lab Invest* 46:16-23, 1982
10. READ SM, NORTHCOTE DM: Minimization of variation in the response to different proteins of the Coomassie blue G dye-binding assay for protein. *Anal Biochem* 116:53-64, 1981
11. WEIBEL ER: *Stereological Methods—Practical Methods for Biological Morphometry*. London, Academic Press, 1979
12. HOSTETTER TH, OLSON JL, RENNKE HG, VENKATACHALAM MA, BRENNER BM: Hyperfiltration in remnant nephrons: A potentially adverse response to renal ablation. *Am J Physiol* 241:F85-F93, 1981
13. OLSON JL, HOSTETTER TH, RENNKE HG, BRENNER BM, VENKATACHALAM MA: Altered glomerular permselectivity and progressive sclerosis following extreme ablation of renal mass. *Kidney Int* 22:112-126, 1982
14. BRENNER BM: Nephron adaptation to renal injury or ablation. *Am J Physiol* 249:F334-F337, 1985
15. FOGO A, YOSHIDA Y, ICHIKAWA I, GLICK AD: Hypertrophic glomeruli and possible relationship to glomerular sclerosis. (abstract) *Lab Invest* 58:31A, 1988
16. YOSHIDA Y, FOGO A, ICHIKAWA I: Glomerular hypertrophy has a greater impact on glomerular sclerosis than the adaptive hyperfunction in remnant nephrons. (abstract) *Kidney Int* 33:327, 1988
17. YOSHIDA Y, FOGO A, ICHIKAWA I: Glomerular hemodynamic changes vs. hypertrophy in experimental glomerular sclerosis. *Kidney Int* 35:654-660, 1989
18. DWORKIN LD, PARKER M, FEINER HD: Nifedipine decreases glomerular injury in rats with remnant kidneys by inhibiting glomerular hypertrophy. (abstract) *Kidney Int* 35:427, 1989
19. WESTENEND PJ, NOOYEN Y, WEENING JJ: Resistance to focal glomerulosclerosis (FSG) after unilateral nephrectomy (UN) in WKY rats is compatible with glomerular hypertrophy. (abstract) *Kidney Int* 35:439, 1989
20. FRIES JU, SANDSTROM D, MEYER TW, RENNKE HG: Glomerular hypertrophy and epithelial cell injury are determinants of progressive glomerulosclerosis in the rat. *Lab Invest* 60:205-209, 1989